



Importance of Differential Diagnosis in Patients with Community-Acquired Pneumonia Using K-9 Drugs (spice)

Importância do diagnóstico diferencial em pacientes com Pneumonia Adquirida na Comunidade, em uso de drogas K-9 (spice)
Importancia del diagnóstico diferencial en pacientes con Neumonía Adquirida en la Comunidad que consumen drogas K-9 (spice)

Site doi: <https://doi.org/10.17058/reci.v15i2.20061>

Submitted: 11/29/2024

Accepted: 05/14/2025

Available online: 07/09/2027

Corresponding author:

E-mail: aztalk@gmail.com

Address: Abraão Caixe Street, 380, Ribeirão Preto, São Paulo, Brazil.

André Zitelli¹

Álvaro Henrique Volpini Vilera¹

Larissa Pereira da Silva¹

Luis Gustavo Durante Bacelar¹

Luiz Paulo Furtado Pompolim¹

Victor de Albuquerque Orsolin¹

Silvia Nunes Szente Fonseca¹

¹University Center Estácio Idomed, Ribeirão Preto, São Paulo, Brazil.

ABSTRACT

Community-acquired pneumonia (CAP) is a condition with high morbidity and mortality, particularly among users of inhaled drugs. The use of the synthetic drug K9 (spice) has been associated with chemical pneumonitis, whose clinical presentation can mimic respiratory infections, complicating diagnosis and appropriate management. This study reports the case of a 33-year-old male patient with a history of substance dependence and recent K9 use, who was hospitalized with severe respiratory failure. Laboratory tests, chest computed tomography, and microbiological and molecular analyses for infectious agents were performed. Initial treatment included empirical antibiotic therapy, invasive ventilatory support, and systemic corticosteroids. The absence of identifiable pathogens and compatible radiological findings led to the diagnosis of K9-induced chemical pneumonitis. Corticosteroid therapy resulted in progressive clinical improvement, allowing extubation and hospital discharge after 24 days, with referral for rehabilitation. This case highlights the importance of considering synthetic drugs in the differential diagnosis of CAP in young individuals with a history of substance use, preventing unnecessary antibiotic use and ensuring more targeted treatment. Additionally, it underscores the need for professional training to recognize clinical and radiological patterns suggestive of chemical pneumonitis, as well as the development of public policies aimed at preventing synthetic drug use and mitigating its impact on public health.

Keywords: *Pneumonia. Pneumonitis. Illicit drugs. Substance abuse.*

RESUMO

A Pneumonia Adquirida na Comunidade (PAC) é uma condição de alta morbimortalidade, especialmente em usuários de drogas inalatórias. O uso da droga sintética K9 (*spice*) tem sido associado à pneumonite química, cujo quadro clínico pode ser confundido com infecções respiratórias, dificultando o diagnóstico e o manejo adequado. Este estudo relata o caso de um paciente masculino, 33 anos, com dependência química e uso recente de K9, internado com insuficiência respiratória grave. Foram realizados exames laboratoriais, tomografia computadorizada de tórax e pesquisa de agentes infecciosos por culturas microbiológicas e testes moleculares. O tratamento inicial incluiu antibioticoterapia empírica, suporte ventilatório invasivo e corticosteroides sistêmicos. A ausência de patógenos identificáveis e os achados radiológicos compatíveis levaram ao diagnóstico de pneumonite química induzida por K9. A terapia com corticosteroides promoveu melhora progressiva, permitindo a extubação e alta hospitalar após 24 dias, com encaminhamento para reabilitação. O caso destaca a importância de considerar drogas sintéticas no diagnóstico diferencial da PAC em indivíduos jovens com histórico de uso de substâncias, evitando o uso desnecessário de antibióticos e garantindo um tratamento mais direcionado. Além disso, evidencia a necessidade de capacitação profissional para o reconhecimento de padrões clínicos e radiológicos sugestivos de pneumonite química, bem como o desenvolvimento de políticas públicas voltadas à prevenção do consumo de drogas sintéticas e à mitigação de seus impactos na saúde pública.

Descritores: *Pneumonia. Pneumonite. Drogas ilícitas. Dependentes químicos.*

RESUMEN

La Neumonía Adquirida en la Comunidad (NAC) es una condición con alta morbilidad y mortalidad, especialmente en usuarios de drogas inhalatorias. El consumo de la droga sintética K9 (*spice*) se ha asociado con neumonitis química, cuya presentación clínica puede confundirse con infecciones respiratorias, dificultando el diagnóstico y el manejo adecuados. Este estudio reporta el caso de un paciente masculino de 33 años, con antecedentes de dependencia a sustancias y consumo reciente de K9, hospitalizado con insuficiencia respiratoria grave. Se realizaron análisis de laboratorio, tomografía computarizada de tórax y estudios microbiológicos y moleculares para detección de agentes infecciosos. El tratamiento inicial incluyó antibioticoterapia empírica, soporte ventilatorio invasivo y corticosteroides sistémicos. La ausencia de patógenos identificables y los hallazgos radiológicos compatibles llevaron al diagnóstico de neumonitis química inducida por K9. La terapia con corticosteroides resultó en una mejoría clínica progresiva, permitiendo la extubación y el alta hospitalaria tras 24 días, con derivación a rehabilitación. Este caso destaca la importancia de considerar las drogas sintéticas en el diagnóstico diferencial de la NAC en individuos jóvenes con antecedentes de consumo de sustancias, evitando el uso innecesario de antibióticos y asegurando un tratamiento más adecuado. Además, evidencia la necesidad de capacitar a los profesionales de la salud para reconocer patrones clínicos y radiológicos sugestivos de neumonitis química, así como de desarrollar políticas públicas dirigidas a prevenir el consumo de drogas sintéticas y mitigar sus impactos en la salud pública.

Palabras Clave: *Neumonía. Neumonitis. Drogas ilícitas. Abuso de sustancias.*

INTRODUCTION

Pneumonia is an inflammation of the lungs often associated with bacterial, viral, or fungal infections. However, beyond infectious agents, non-infectious factors such as the inhalation of toxic substances can trigger severe pulmonary inflammatory processes. The use of inhaled drugs represents a significant risk factor for lung diseases due to their deleterious effects on the respiratory epithelium, impairing pulmonary defense mechanisms and increasing susceptibility to infections, including pneumonia.^{1,2}

Community-acquired pneumonia (CAP) remains one of the leading causes of global morbidity and mortality. According to data from the Department of Informatics of the Brazilian Unified Health System (DATASUS), in 2023, there were 655,827 hospitalizations due to pneumonia and 65,109 related deaths across all regions of Brazil. This scenario underscores the need for studies that investigate aggravating factors of CAP, including the influence of illicit substance use.^{3,4}

Chemical pneumonitis is an acute form of pulmonary inflammation that results from the inhalation or aspiration of toxic substances, such as vapors, gases, fumes, or irritating liquids.⁵ Inhaled drugs like cocaine, crack, heroin, and volatile solvents can cause direct damage to the upper and lower airways, compromising ciliary function and reducing the respiratory system's ability to eliminate pathogens. This facilitates the development of severe pulmonary infections, including viral and bacterial pneumonia.^{6,7}

In recent years, the emergence of synthetic drugs from the K class (such as K2, K4, K9, Spice, and K12) has posed a new challenge to public health. These substances, initially developed for pharmacological research, are often marketed as cannabis alternatives and misleadingly referred to as "synthetic marijuana." However, their mechanisms of action and effects on the body are significantly different and often more potent and dangerous.⁸ The drug K9, in particular, has been linked to several serious adverse effects, including respiratory, cardiovascular, and neurological complications.⁹

Given this scenario, this study aimed to report a case of chemical pneumonitis associated with the use of the synthetic drug K9, emphasizing its relevance in differential diagnosis and appropriate clinical management. Understanding the respiratory impacts of these substances is essential to improving diagnosis, treatment, and prevention strategies, thereby reducing risks to public health.

CASE DESCRIPTION

A 33-year-old male patient with a history of asthma, anxiety disorder, untreated chronic heart failure, chronic

alcoholism, and marijuana, crack, and cocaine use since age 15, with several unsuccessful hospitalizations for chemical dependency treatment and rehabilitation, and recent use of K9.

The patient sought medical care at the emergency room with a history of asthenia, fever, productive cough with purulent sputum associated with progressive dyspnea for 7 days. Due to marked worsening on the date of admission, he was immediately transferred to a general hospital. Upon arrival, the patient was drowsy, confused, tachypneic, with a respiratory rate of 30 breaths per minute, using accessory muscles, and had low oxygen saturation, requiring a reservoir mask at 10 L/min to achieve an oxygen saturation of 92%.

Radiographic images showed diffuse interstitial involvement, alveolar opacities in the middle lung fields and at the right base, as well as an enlarged heart area (Figure 1).

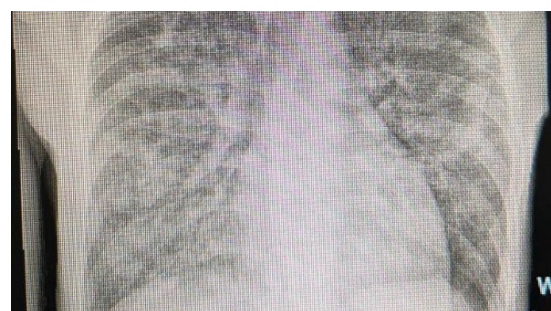

Figure 1. Chest X-ray of the patient at the time care was initiated.

He was transferred to the intensive care unit (ICU), where he required orotracheal intubation and mechanical ventilation. Shortly after sedation began, he developed hypotension, and vasoactive drugs were administered. Due to pulmonary impairment, continuous intravenous infusion of a neuromuscular blocker was required.

Initial diagnostic hypotheses included septic shock of pulmonary origin, secondary to severe community-acquired pneumonia, with possible bacterial, viral, or fungal etiology. Severe pneumonia caused by *Mycobacterium tuberculosis*, SARS-CoV-2 pneumonia (Covid-19), and congestive heart failure (profile C) were also considered as differential diagnoses.

Additional tests were performed, including complete blood count, blood culture, urine culture, tracheal culture, smear test for BAAR (3 samples), serology for HIV, VDRL, HbsAg, Anti-HCV, Covid-19, influenza, all with negative results, as well as imaging tests such as X-ray, CT scan, and chest ultrasound. On February 10th, empirical treatment with levofloxacin, oxacillin, and fluconazole was initiated, and the patient remained on these medications for 10 days.

Given that all tests returned negative and considering family-reported information regarding the patient's long-term drug use — with recent use of the synthetic

substance K9 — the working diagnosis of chemical pneumonitis associated with K9 inhalation was established. Corticosteroids were administered at anti-inflammatory doses, leading to an improvement in hypoxia and facilitating progressive weaning from mechanical ventilation.

The patient remained in the ICU for 17 days, with 11 days of invasive mechanical ventilation. After extubation, while still in the ICU, he developed hyperactive delirium and withdrawal syndrome. He was later transferred to the internal medicine ward, where he remained hospitalized for another 7 days, showing significant improvement in both pulmonary function and substance withdrawal symptoms. He was discharged from the hospital and referred to a rehabilitation clinic (Figure 2).

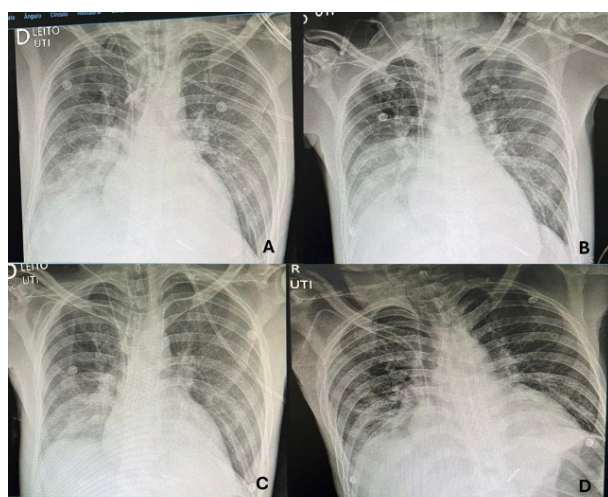


Figure 2. Sequence of chest X-rays showing improvement in the patient's clinical condition.

The study was conducted in accordance with the ethical standards outlined in Resolutions 466/2012 and 580/2018 of the Brazilian Ministry of Health. It was approved by the Research Ethics Committee (CEP) on July 28, 2017, under opinion no. 2.190.929 and CAAE (Certificate of Presentation for Ethical Consideration) no. 70623317.7.0000.5581.

DISCUSSION

Community-acquired pneumonia (CAP) is a common pulmonary infection caused by a variety of pathogens, including bacteria, viruses, and fungi. During the Covid-19 pandemic, there was a significant increase in CAP cases, often complicating the differentiation between SARS-CoV-2 infection and other etiologies.¹⁰ Additionally, the strain on healthcare systems underscored the need for accurate diagnoses to optimize patient management and reduce hospital costs.¹¹

The diagnosis of CAP is primarily based on clinical and radiological evaluation, with chest radiography being a key diagnostic tool. However, distinguishing

CAP from Covid-19 can be challenging due to overlapping symptoms, such as fever, cough, and dyspnea. Although specific signs, like anosmia and ageusia, may suggest a viral origin, these can also be present in CAP.⁸ In the present case, the absence of identifiable pathogens combined with a history of synthetic drug use (K9) pointed toward a diagnosis of chemical pneumonitis.

Chemical pneumonia related to illicit drug use — especially via inhalation or intravenous routes — constitutes a form of toxic pneumonitis caused by the inhalation or aspiration of lung-irritating substances. In such cases, the inflammatory response is initially sterile, triggered by chemical compounds found in substances like crack, methamphetamine, heroin, or K9. However, bacterial infections often overlap, especially in chronic and immunocompromised individuals, which characterizes secondary CAP. The main associated etiological agents include *Streptococcus pneumoniae*, *Staphylococcus aureus* (including MRSA), *Klebsiella pneumoniae*, and, in more severe cases, *Pseudomonas aeruginosa* and oral anaerobes, especially in contexts of aspiration with decreased level of consciousness. Proper identification of the etiology — chemical, infectious, or mixed — is essential to guide treatment, which may range from ventilatory support and anti-inflammatory measures to specific antibiotic therapy.^{11,13,14}

The use of inhaled drugs such as cocaine and crack is a recognized risk factor for pulmonary injuries, including chemical pneumonitis, bronchospasm, and alveolar hemorrhage.⁹ However, the patient had chronic use of these substances without previous severe respiratory episodes, suggesting a possible specific effect of K9 in exacerbating the condition. K9 and other synthetic cannabinoids can trigger severe pulmonary inflammatory reactions, leading to the need for intensive ventilatory support.¹⁶

The most common pathogens associated with CAP include *Streptococcus pneumoniae*, followed by *Haemophilus influenzae*, *Mycoplasma pneumoniae*, and respiratory viruses such as influenza and SARS-CoV-2. Immunocompromised individuals, such as those with untreated HIV, are at higher risk for opportunistic infections like pneumocystosis and tuberculosis.¹⁷ The use of illicit drugs is also associated with increased susceptibility to respiratory infections, due to both chronic immunosuppression and exposure to unsanitary environments.¹¹

The impact of novel synthetic drugs like K9 remains poorly understood in the scientific literature. Reports suggest these substances can provoke severe pulmonary reactions, leading to more extended hospital stays and high consumption of healthcare resources.¹⁸ Studies show that illicit drug use is on the rise, with a global increase of 23% over the past decade.^{3,4,11} In Brazil, research indicates that millions of individuals have used

illicit substances, with marijuana and cocaine being the most prevalent.^{11,18}

The burden on the healthcare system is significant, as patients with chemical pneumonitis often require intensive ventilatory support, increasing demand for ICU beds and specialized resources. Therefore, implementing preventive strategies and public policies aimed at reducing the use of these substances is essential to prevent further deterioration in public health.^{16,18}

This case highlights the importance of recognizing new synthetic drugs such as K9 in the differential diagnosis of CAP in young patients presenting with severe respiratory symptoms and a history of substance abuse. Early diagnosis can enable more efficient clinical management and avoid unnecessary hospital costs. Furthermore, it underscores the need for healthcare professionals to be trained to recognize clinical and radiological patterns suggestive of synthetic drug-related chemical pneumonitis, allowing for more targeted and effective treatment.¹¹

Finally, a warning must be issued to health authorities to prepare for a potential rise in hospital admissions related to this new class of drugs. Epidemiological surveillance measures, awareness campaigns, and investments in professional training are essential to mitigate the impact of these substances on the healthcare system.

REFERENCES

1. United Nations Office on Drugs and Crime (UNODC). World Drug Report 2023. Vienna: UNODC; 2023. Disponível em: <https://www.unodc.org/unodc/en/data-and-analysis/world-drug-report-2023.html>
2. Smith RJ, Thompson M, Garcia J. Effects of inhaled substances on pulmonary immunity: a review. *Respir Med.* 2021;175:106190. <https://doi.org/10.1016/j.rmed.2020.106190>
3. Ministério da Saúde. Sistema de Informação Hospitalar do SUS (SIH/SUS). Datasus; 2023. Disponível em: <http://datasus.saude.gov.br>
4. Oliveira AM, Santos MC, Pereira AC. Fatores de risco associados à pneumonia adquirida na comunidade no Brasil. *J Bras Pneumol.* 2022;48(1):e20210137. <https://doi.org/10.36416/1806-3756/e20210137>
5. Torres A, et al. Chemical pneumonitis: clinical characteristics and management. *Eur Respir J.* 2020;56(5):2000070. <https://doi.org/10.1183/13993003.00070-2020>
6. Zhang X, Li Y. Impact of inhaled drugs on lung function and immune response. *Front Pharmacol.* 2021;12:703914. <https://doi.org/10.3389/fphar.2021.703914>
7. Gonzalez JF, Perez D, Martinez R. Pulmonary toxicity related to illicit drugs: mechanisms and clinical presentations. *Pulm Pharmacol Ther.* 2022;74:102081. <https://doi.org/10.1016/j.pupt.2021.102081>
8. Jones L, et al. Synthetic cannabinoids: a review of pharmacology, toxicology, and public health impact. *Drug Alcohol Depend.* 2020;215:108199. <https://doi.org/10.1016/j.drugalcdep.2020.108199>

9. Williams K, et al. Respiratory complications from synthetic cannabinoid use: a clinical overview. *Chest.* 2021;159(3):1093-1101. <https://doi.org/10.1016/j.chest.2020.09.007>
10. Jain S, et al. Community-acquired pneumonia during COVID-19 pandemic: clinical challenges. *J Infect Dis.* 2021;223(10):1626-1634. <https://doi.org/10.1093/infdis/jiaa742>
11. Kim S, et al. Hospital outcomes of community-acquired pneumonia: influence of drug use and comorbidities. *Clin Infect Dis.* 2022;74(1):132-140. <https://doi.org/10.1093/cid/ciab849>
12. Lee N, et al. Differentiating COVID-19 pneumonia from other causes: clinical and radiological clues. *Respir Med.* 2021;182:106399. <https://doi.org/10.1016/j.rmed.2021.106399>
13. Polverino E, Torres A. Community-acquired pneumonia and novel drugs. *Future Microbiol.* 2015;10(11):1797-817. <https://doi.org/10.2217/fmb.15.91>
14. Torres A, et al. Advances in bacterial pneumonia diagnosis and treatment. *Lancet Infect Dis.* 2019;19(5):e155-e164. [https://doi.org/10.1016/S1473-3099\(18\)30517-4](https://doi.org/10.1016/S1473-3099(18)30517-4)
15. Wood DM, Dargan PI. Novel psychoactive substances: understanding acute toxicity. *Ther Drug Monit.* 2012;34(4):363-7. <https://doi.org/10.1097/FTD.0b013e31825b954b>
16. Seely KA, et al. Synthetic cannabinoids and severe pulmonary toxicity: clinical insights. *Pulm Pharmacol Ther.* 2023;77:102158. <https://doi.org/10.1016/j.pupt.2022.102158>
17. GBD 2016 Alcohol and Drug Use Collaborators. Global burden of disease attributable to substance use: a systematic analysis. *Lancet Psychiatry.* 2018;5(12):987-1012. [https://doi.org/10.1016/S2215-0366\(18\)30337-7](https://doi.org/10.1016/S2215-0366(18)30337-7)
18. Monteiro MG, et al. Drug policy and health system challenges: impact on respiratory disease burden. *Rev Saude Publica.* 2020;54:61. <https://doi.org/10.11606/s1518-8787.2020054002340>

AUTHORS' CONTRIBUTIONS

André Zitelli contributed to the bibliographic research, writing of the abstract, introduction, methodology, discussion, interpretation and description of the results, conclusions, review, and acquisition of funds. **Álvaro Henrique Volpini Vilera** contributed to the bibliographic research, writing of the abstract, introduction, methodology, discussion, interpretation and description of the results, conclusions, and review. **Larissa Pereira da Silva** contributed to the bibliographic research, writing of the abstract, introduction, methodology, discussion, interpretation and description of the results, conclusions, review, and data collection for the report. **Luis Gustavo Durante Bacelar** contributed to project management, writing of the abstract, methodology, interpretation of the results, conclusions, review, and formatting of references. **Luiz Paulo Furtado Pompolim** contributed to project management, fund acquisition, bibliographic research, and review. **Victor de Albuquerque Orsolin** contributed to the bibliographic research, writing of the abstract, introduction, methodology, discussion, interpretation and description of the results, conclusions, review, and translation. **Sílvia Nunes Szente Fonseca** acted as advisor, contributing with corrections and editing.

All authors approved the final version to be published and are responsible for all aspects of the work, including ensuring its accuracy and integrity.

Please cite this article as: Zitelli A, Vilera AHV, da Silva LP, Bacelar LGD, Pompolim LPF, Orsolin VA, Fonseca SNS. Importance of Differential Diagnosis in Patients with Community-Acquired Pneumonia Using K-9 Drugs (spice). Rev Epidemiol Control Infect [Internet]. 2025 Jul. 15; 15(2). Available from: <https://seer.unisc.br/index.php/epidemiologia/article/view/20061>